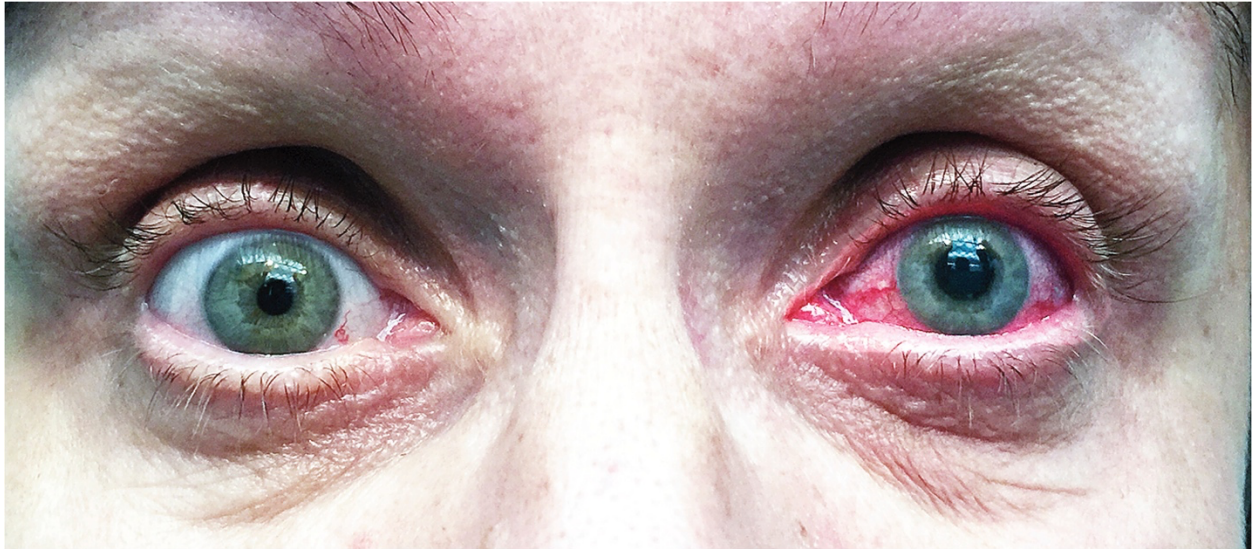

Dine and Learn January 14, Cases

1. 60 year old female with pain, vision loss, headache after entering dark room

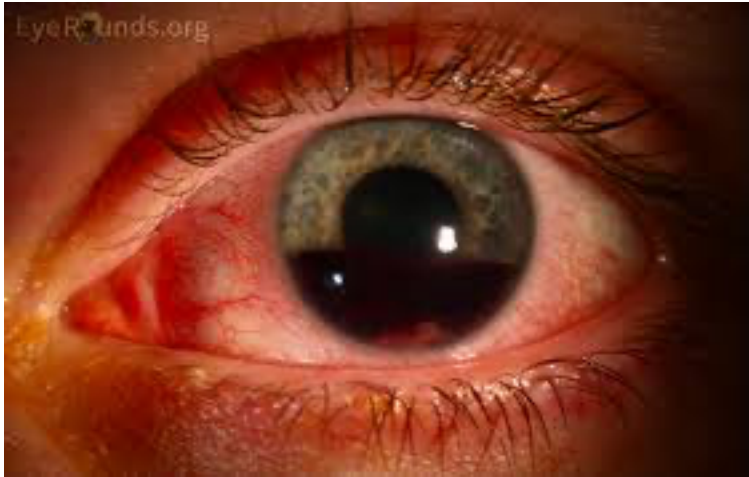

Heiko Pohl, M.D., and Alexander A. Tarnutzer, M.D., Acute Angle-Closure Glaucoma, Published March 7, 2018, N Engl J Med 2018;378: e14, DOI: 10.1056/NEJMicm1712742, VOL. 378 NO. 10

- Pain? ++++
- Photophobia? +/-
- Vision loss? +
- Foreign body sensation? -
- Trauma, occupational or environmental exposure, or recent surgery? -
- Contact lenses? -

- Acuity: reduced
- Fields: normal
- Pupils: fixed mid-dilated
- EOM: normal
- Anterior Segment: shallow with hazy, edematous cornea
- IOP: 40

2. 20 YO male punched in the face

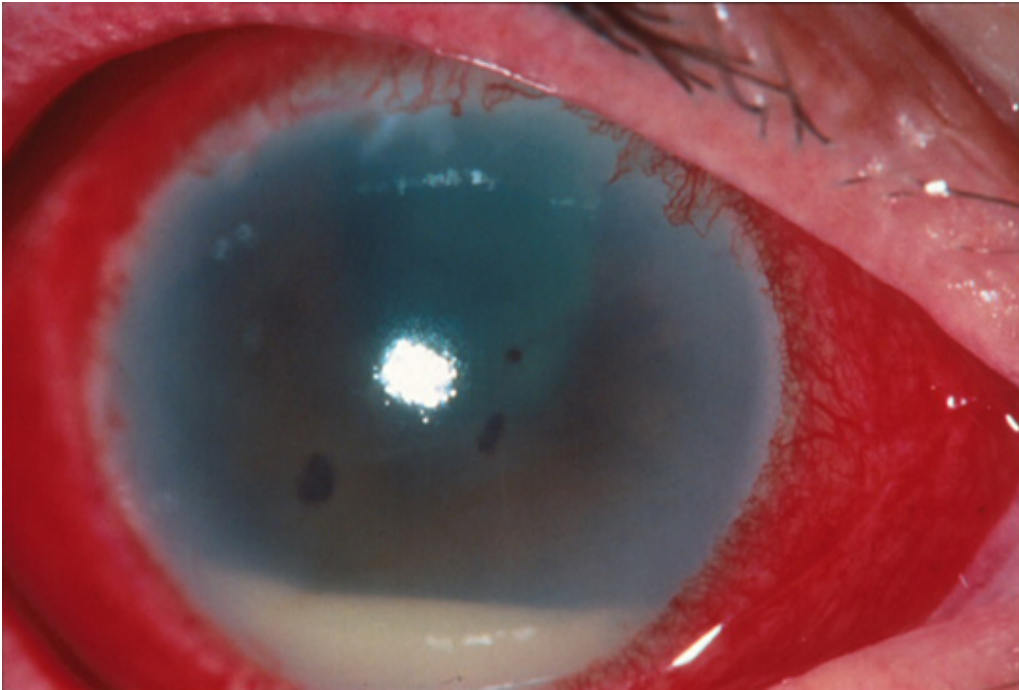


Emma Hartness, BS; Arnulfo Garza Reyes, MD; Caroline Yu, MD; Nathaniel Sears, MD, Hyphema Diagnosis and Management, <https://eyerounds.org/cases/345-hyphema.htm#gsc.tab=0>, February 20, 2024

- Pain? -
- Photophobia? +/-
- Vision loss? +
- Foreign body sensation? -
- Trauma, occupational or environmental exposure, or recent surgery? +
- Contact lenses? -

- Acuity: reduced
- Fields: deficit
- Pupils: normal
- EOM: normal
- Anterior Segment: RBC level seen
- IOP: 27

3. 40 YO female active IDU presents with vision loss



https://www.uptodate.com/contents/bacterial-endophthalmitis?search=red%20eye&topicRef=6900&source=see_link

- Pain? +
- Photophobia? +
- Vision loss? +
- Foreign body sensation? -
- Trauma, occupational or environmental exposure, or recent surgery? -
- Contact lenses? -

- Acuity: reduced
- Fields: deficit
- Pupils: normal
- EOM: normal
- Anterior Segment: WBC level
- IOP: 18

4. 50 YO F with history of Lupus, eye pain and photophobia

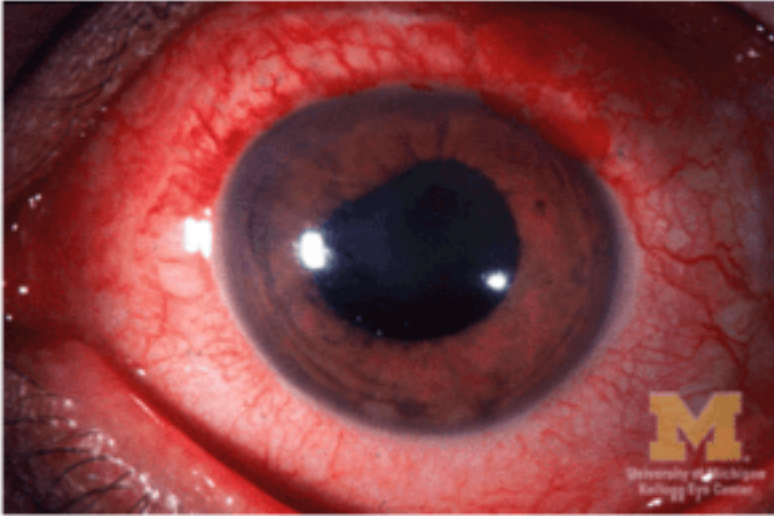


Figure 7 -
http://kellogg.umich.edu/theeyeshaveit/redeye/anterior_uveitis.html

- Pain? +
- Photophobia? +, including consensual photophobia
- Vision loss? Subtle
- Foreign body sensation? -
- Trauma, occupational or environmental exposure, or recent surgery? -
- Contact lenses? -

- Acuity: slightly reduced
- Fields: normal
- Pupils: misshapen due to iris adhesion to anterior lens surface
- EOM: normal
- Anterior Segment: cells/flare, ciliary flush
- IOP: 12

5. 40 yo Female with dermatomal rash on forehead and eye irritation

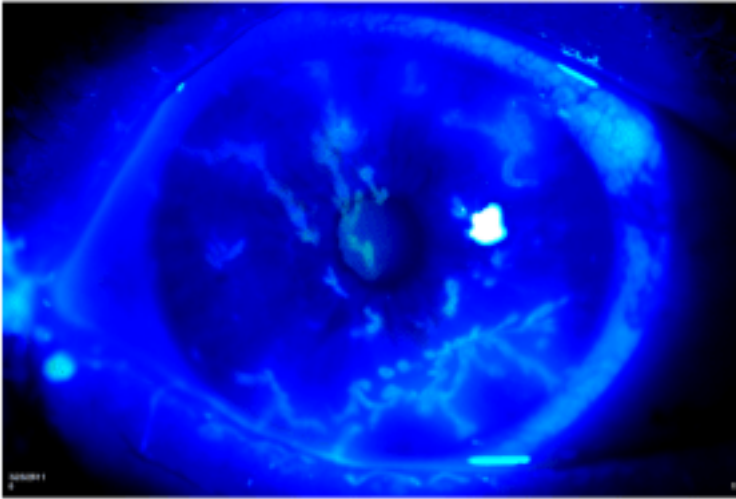


Figure 11 - http://oogziekenhuis.me/Herpes_Zoster/Herpes_Zoster.html

- Pain? +
- Photophobia? +
- Vision loss? +
- Foreign body sensation? +
- Trauma, occupational or environmental exposure, or recent surgery? -
- Contact lenses? -

- Acuity: slightly decreased
- Fields: normal
- Pupils: normal
- EOM: normal
- Anterior Segment: fluorescein exam shows pseudodendrites without terminal bulb
- IOP: normal

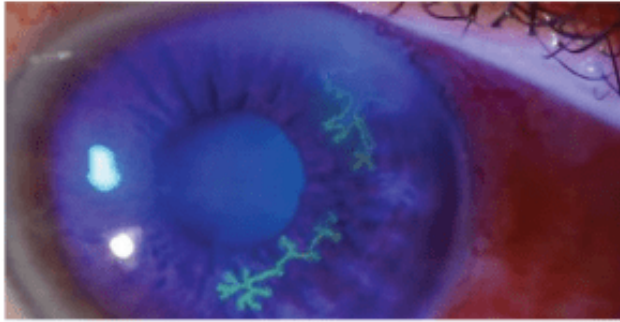


Figure 10 -
<https://onlinelibrary.wiley.com/doi/abs/10.1111/ceo.12785>

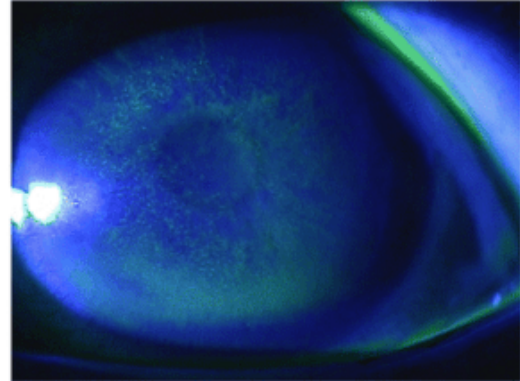
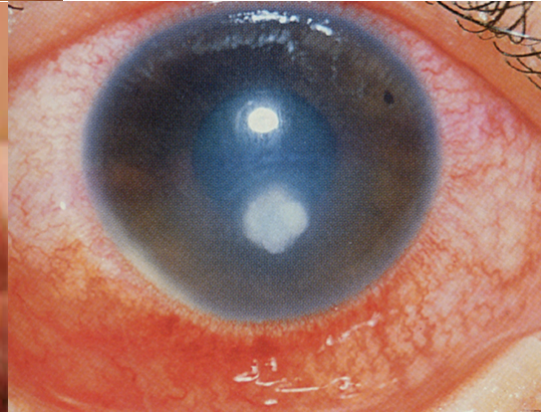
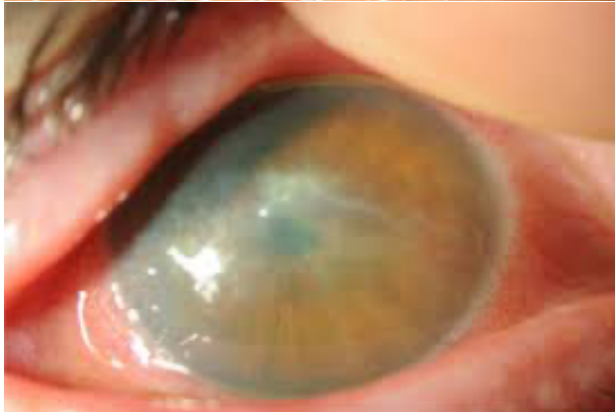
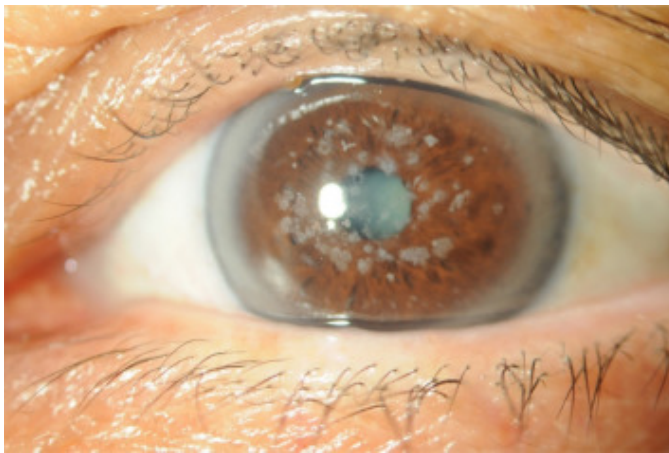


Figure 12 - Kwon DH, Moon JD, Park WJ, et al. Case series of keratitis in poultry abattoir workers induced by exposure to the ultraviolet disinfection lamp. *Ann Occup Environ Med.* 2016;28:3. Published 2016 Jan 15. doi:10.1186/s40557-015-0087-7



6. 35 yo Male feels like something stuck in eye after gardening yesterday

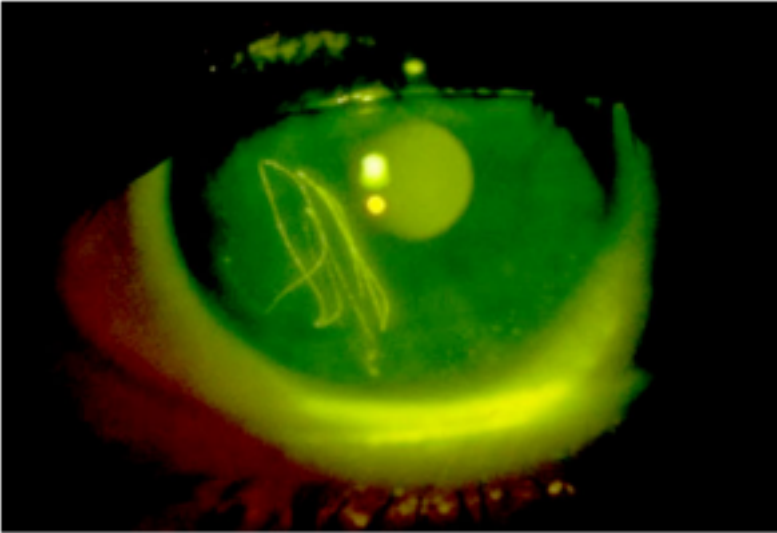


Figure 6 - <http://www.seueyeclinic.com/our-services>

- Pain? +
- Photophobia? +
- Vision loss? +/-
- Foreign body sensation? +
- Trauma, occupational or environmental exposure, or recent surgery? +
- Contact lenses? -

- Acuity: normal
- Fields: normal
- Pupils: normal
- EOM: normal
- Anterior Segment: fluorescein uptake in linear pattern
- IOP: normal

7. 20 YO male stabbed in the eye

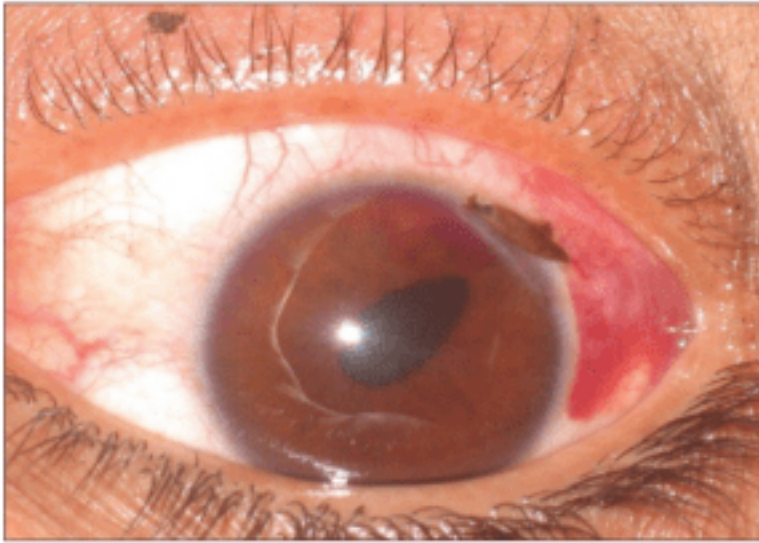


Figure 5 - <https://theretinainstitute.org/open-globe-injury>